

DOCUMENT CONTROL PAGE	
Title	Title: Colour Duplex of the Extracranial Carotid Arteries Version: 5.0 Reference Number: CAR005
Supersedes	Supersedes: CAR004 Guidance on how to report plaque in large bulb
Minor Amendment	Notified to: VASCULAR SCIENTIST Date: 27/3/2020 21/09/2020: Refer to Infection control policy (MY) 21/09/2020: Include subclavian artery in images saved (MY) Version 4: 15/02/2021: carotid screening (MY) Version 5: 17/05/2021: stent surveillance (MY)
Author	Originated/Modified by: H Edlin Designation: Vasc lab Manager
Ratification	Ratified by: Clinical effectiveness group march 2020 (JVS, TRA, NAH)
Application	
Circulation	Issue date: 27/4/18 Circulated by: H Edlin Dissemination & Implementation: Email
Review	Review Date: March 2022 Responsibility of: Manager
<div> <div>Date Placed on S:drive: 17/05/2021</div> <div>EqlA Registration Number:</div> </div>	

Reasons for performing the test

Ultrasound can be used to evaluate the extracranial cerebral circulation in order to investigate patients who may be at risk of suffering or those who have suffered a TIA or stroke.

Many centres now use ultrasound examination to select patients directly for surgery without preoperative angiography, as angiography is known to carry its own risks of transient and neurological deficit.

Common Indications

Transient ischemic attacks (TIA)

Amaurosis fugax

Carotid bruit

Cerebrovascular Accident (CVA)

Follow-up of known carotid stenosis

Trauma in the distribution of the carotid artery e.g. suspected dissection, arteriovenous fistula or pseudoaneurysm

Pre-operative assessment for high risk patients e.g. coronary artery bypass surgery (CABG)

Pulsatile neck masses

Evaluation of suspected subclavian steal syndrome

Contraindications and Limitations

Patients with short, thick muscular necks

Patients who have had recent surgery, ultrasound visualisation may be limited due to oedema, haematoma, surgical staples, dressings etc

Calcified plaque may cause acoustic shadowing limiting Doppler and B-mode image assessment.

Patients who are unable to lie flat due to pre-existing co-morbidities e.g. chronic obstructive pulmonary disease (COPD) and arthritis – although these patients may be able to tolerate being examined seated in a chair or with the head of the bed raised

Patients who are unable to cooperate due to reduced cognitive functions e.g. Alzheimer's or dementia and through involuntary movements

Examinations undertaken portably at the patient's bedside maybe limited due to equipment and room dimensions.

Equipment used

- Colour Duplex scanner

- Continuous wave Doppler
- Blood pressure cuff
- Sphygmomanometer

Service and quality control test are carried out by supplier/Christie medical physics

Consumables required

- Ultrasound gel
- Tissues
- Paper roll for the couch
-

Patient preparation

Identify yourself and ensure the patients are at ease by explaining the test to be carried out is a safe and painless procedure. Ensure patient can understand and they consent to the procedure, offering an interpreter if one has not already been arranged. Obtain relevant clinical history to ensure correct test has been ordered, adapting the test performed to the patients symptoms and clinical findings (discuss with senior member of staff).

Ensure that the patient is correctly identified using 3 forms of ID – these are usually name, date of birth and first line of address (this can also include wrist band ID)

Procedure

A 7-4 MHz linear array transducer is used with optimal settings for a carotid duplex scan.

The patient should be examined in a supine position with the head tilted and rotated away from the side being examined, in order to maximise exposure of the patient's neck.

Survey the proximal common carotid artery (CCA) in B-mode followed by colour-flow in a longitudinal plane, scanning distally to the bifurcation where the internal and external carotid arteries (ICA & ECA) can usually be located (with the internal situated posterolaterally, and external anteromedially - although this is NOT ALWAYS the case).

Using the Doppler, create an angle that is suitably parallel to the flow direction and is at an angle of 60° or less (3). Always ensure that the transmitting frequency, angle, sample volume size, PRF, colour box size and direction, focus, and gain settings etc are correct. Measure the peak systolic and end diastolic velocities (PSV & EDV) of the CCA approximately 2cm proximal to the bifurcation and the ICA approximately 1-2cm distal to the bifurcation or where the highest velocity is detected. Measure the PSV of the ECA in a similar way. Measurements should always be taken in the centre of the lumen.

With all settings correct, turbulent flow, incomplete colour filling or high velocities suggests presence of a lesion.

If there is plaque present, the plaque morphology and distance from bifurcation should be recorded.

The CCA, ICA and ECA should then be examined in transverse plane in B-mode and color Doppler.

Vertebral Arteries

Due to the position of the vertebral arteries, a full study cannot be performed. Short segments of the vertebral artery can be visualised if the transducer is angled posteriorly. The flow direction is checked using the colour Doppler, but more importantly using spectral Doppler.

If there is any suspicion of vertebral artery disease or subclavian steal then a full vertebral artery test should be performed.

To perform a full assessment of the vertebral arteries, a blood pressure cuff should be inflated around the upper arm for one minute occluding the brachial artery.

Whilst imaging and sampling the vertebral artery on colour duplex, release the cuff. If there is any significant steal syndrome the vertebral arterial flow will temporarily be retrograde.

Subclavian Arteries

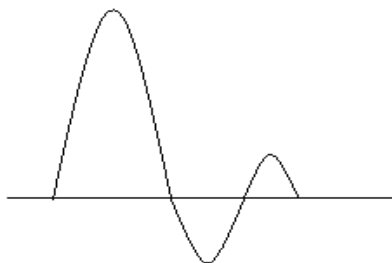
Subclavian Steal Syndrome (SSS)

The main objective in assessing the subclavian artery is to identify the presence of a proximal stenosis or occlusion of the proximal subclavian artery and establish a diagnosis of subclavian steal syndrome (SSS). This phenomenon occurs where there is significant stenosis or occlusion of the subclavian artery proximal to the origin of the ipsilateral vertebral artery. The pressure distal to the disease is reduced compared to that at the junction of the vertebral artery resulting in retrograde flow down the vertebral artery on the side of the stenosis to supply the upper extremity and subclavian branches. Due to the presence of the lesion in the subclavian artery, spectral Doppler waveform of the subclavian artery is abnormal.

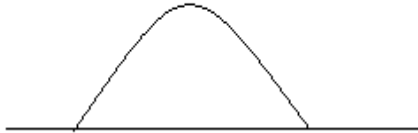In a transverse plane, the CCA is traced proximally towards the clavicle and the transducer is angled beneath the clavicle until the subclavian artery is viewed in a longitudinal section. High velocities or turbulence detected on spectral Doppler in the subclavian artery or abnormal waveform characteristics should be noted on the report.

Spectral Doppler waveform characteristics:

Triphasic waveform - normal flow:



Monophasic waveform - disease present proximal to pulse point:



Results

B-mode

The following points must be noted regarding CCA, ICA, and ECA.

- Patency as seen by the outward compliance movement of the walls and movement of the red cell aggregates in the lumen.
- Anatomical variation in calibre, anatomy and/or course of vessels.
- Presence of intimal thickening or plaque.
- Site, extent and severity of plaque.
- Type of plaque.

Plaque Morphology

In B-mode, plaque morphology should be examined and noted. (2, 3, 4)

Grading:

- Soft: Echolucent plaque, similar echogenicity to that of blood.
- Mixed: Variable echogenicity, some areas echogenic and some areas echolucent.
- Calcified: Acoustic shadowing cast from the plaque.
- Ulcerative: Area of mixed plaque forming a 'crater' filled with either soft plaque (seen in transverse plane as a 'hook' of mixed plaque surrounding soft plaque), or with blood visibly swirling within the crater.

Please indicate on the report whether there is evidence of an ulcer present or not.

Doppler

The interpretation of a carotid examination relies upon the accurate and methodical collection of Doppler information that is confirmed (or modified) by the appearance of the B-mode image and the colour filling.

Velocity criteria for ICA stenosis (This should be used as a guide, other factors such as contralateral disease, cardiac output should be taken in to account, see 'pitfalls' below):

<i>Colour Duplex of the Extracranial Carotid Arteries CAR005</i>	<i>Page 5 of 9</i>
<i>Version 5.0</i>	

Vascular Society and SVT recommended ⁽¹⁾				
% Stenosis	PSV	EDV ⁽⁵⁾	ICA PSV/ CCA PSV ratio	ICA PSV/CCA EDV ratio
<50	<125	<40	<2	<8
50-59	>125	40-100	2-4	8-10
60-69		40-100		11-13
70-79	>230	>100	>4.0	14-21
80-89		>100		22-29
>90 but < near occlusion	>400	>100	>5.0	>30
Near occlusion	high, low or string flow	variable	variable	variable
Occlusion	No flow	N/A	N/A	N/A

Oates CP et al., Joint Recommendations for Reporting Carotid Ultrasound Investigations in the United Kingdom, Eur J Vasc Endovasc Surg (2008)

Carotid artery stenosis: grey-scale and Doppler ultrasound diagnosis – Society of Radiologists in Ultrasound Consensus Conference' Grant EG et al Radiology 2003; 229: 340-346

Be aware of other conditions ie fibro-muscular dysplasia, more prominent in females in their 50's. Colour flow disturbance and increase velocities in the absence of significant atherosclerotic plaque.

After all the above has been considered, analyse the results and grade the disease. Write the report accordingly.

At the end of the test inform the patient how they will be informed of their results:

OP - informed who their results will be sent back to and an appropriate time scale for follow up.

One stop - Sent back to referrer with a copy of their results or informed who their results will be sent back to with an appropriate time scale for follow up.

A+E - Sent back with their results to the referrer in A+E/ACU as appropriate.

IMPORTANT

If patient has any very severe lesions or you feel that the patient requires a medical/ surgical opinion, let a senior member of staff know, keep the patient in the department whilst someone speaks with a member of the Vascular team.

Write on report that you have sought advice from the vascular team and what the outcome was.

Protocol discussions re large carotid bulb

Velocity grading criteria used as per SVT guidelines and corresponds to NASCET criteria.

If measure % stenosis visually, then this should be taken at the level of stenosis (ECST) make a note on report. Eg

%stenosis

Lt:

Common: minimal (<40%)

Bif: minimal (<40%)

Internal: *

External: minimal (<40%)

Vertebral: orthograde

Conclusion

*Lt: Large carotid bulb: Area of mixed and **soft** plaque in Lt ICA. No raised velocities detected indicating <50% (NASCET), however visually there appears to be 50-59% lumen loss (using ECST criteria)

Bulb vessel diameter = 10.0mm, residual lumen diameter = 4.5mm, ICA vessel diameter = 5.0mm.

The surgeons are more likely to operate if there is a change in flow velocity, rather than just the presence of a stenosis. The plaque morphology is important in these cases.

Stent Surveillance

Patients who have undergone carotid stenting will enter a stent surveillance programme. Referrals will be made to Helen O'Donnell (vascular specialist nurse at Wythenshawe) who will co-ordinate the follow up scans and book patients in with our Lab that live near MRI.

Referrals will come to the vascular lab email. Vascular Lab staff should add them to ICE and attach the referral letter to CRIS.

Scanning procedure is the same. Vascular Specialist Nurse will follow up. For any urgent findings, contact On Call Reg.

In-patients

File report in notes under investigations and write in the case history that the test has been performed and where the results are filed, signing and dating your entry.

GP and non-vascular consultant referrals

If patients results show significant pathology, advise clinician to refer patient to a vascular consultant.

Pitfalls

Colour Duplex of the Extracranial Carotid Arteries CAR005	Page 7 of 9
Version 5.0	

Colour Duplex cannot always distinguish between an occlusion and sub-occlusion of a vessel, therefore on reporting it must only be suggested that the vessel is occluded, and give the reasons that back up the statement; i.e. no flow detected using spectral Doppler, reverse component in the CCA Doppler signal, no flow detected with the power Doppler.

Compensatory flow caused by an occlusion of an ICA. In the ipsilateral ECA and contralateral CCA, ICA and ECA, the compensatory flow is in the form of enhanced velocities but not usually disturbed flow. However, if atheroma is present in the contralateral carotid artery, it can be difficult to distinguish between enhanced velocities due to compensational and those due to stenosis and is probably one of the main causes for over grading stenosis. Grade stenosis as accurately as possible always commenting that there may be a degree of over estimation and reasons why.

Other factors to consider when grading the disease:

1. Proximal occlusion e.g. innominate artery disease or occlusion could cause under estimation of disease present.
2. Distal occlusion of the ICA may be missed, Prox ICA may be patent but abnormal waveform present.
3. Poor cardiac output/ mitral valve disorder may cause under estimation of disease present in carotid arteries. Any abnormal flow in the CCA must be commented on and suggestions of cause of abnormality documented on report.

Aliasing is another problem that occurs when using colour-flow. Aliasing occurs when the true Doppler shift exceeds one half the pulse repetition frequency. Aliasing can be reduced by:

- Increasing the PRF (scale)
- Altering Doppler angle
- Lowering baseline shift
- Reducing operating frequency

Images are also affected by biological variability e.g. Depth of vessels, tortuosity of vessels, high bifurcation and calcification. Always comment on report any difficulties encountered when performing scan. NEVER guess, if unable to conclude or be accurate report as an inconclusive scan, state the reasons and suggest another imaging modality.

The skill and bias of the observer can also alter the results obtained.

Performing carotid scans in bed-bound patients in the lab and portably at the patient's bedside can be particularly difficult and increases the risk of RSI (repetitive strain injury). It is therefore acceptable to perform a carotid screening scan of bilateral CCA and ICA +/- any other vessels that can be easily visualised during the examination. In these cases, report that a limited carotid screening scan was performed and if disease present to re-refer for detailed scan.

Reporting:

The report is a recording and interpretation of observations made during the extracranial carotid arterial duplex ultrasound examination; it should be written by the CVS undertaking the examination and viewed as an integral part of the whole examination

The report should include correct patient demographics; date of examination; examination type and the name and status of the CVS. Document that consent was obtained and whether a chaperone was present.

The reporting should include:

Which arteries have been assessed & record the presence/absence of disease

Qualitatively note the nature of the plaque e.g. calcified, echolucent, irregular, smooth etc, the length and anatomical position

Percentage degree of stenosis and calculation method

Any limitations e.g. calcified plaque causing acoustic shadowing

An appropriate number of annotated images that represent the entire ultrasound examination - in accordance with local protocols and SVT Image Storage Guidelines ⁽⁶⁾

An example of images saved include:

Carotid scan

Subclavian artery

Common carotid velocity

Internal carotid velocity

External carotid velocity

Vertebral artery

Any pathology reported

Patient and staff safety

Use output powers quoted by the manufacturer and in accordance to ALARA / AIUM criteria.

Infection control: see latest Vascular Lab Infection control and working practices policy.

Adjustable couch and chair should be used to reduce the risks of work related upper limb disorders.

Equality Impact Assessment

Colour Duplex of the Extracranial Carotid Arteries CAR005	Page 9 of 9
	Version 5.0

References & Bibliography

1. Oates CP et al., Joint Recommendations for Reporting Carotid Ultrasound Investigations in the United Kingdom, Eur J Vasc Endovasc Surg (2008)
2. De Bray J M, Baud J M, Dauzat M 1997 Consensus concerning the morphology and the risk of carotid plaques. Cerebrovascular Disease 7: 289–296
3. European Carotid Plaque Study Group 1995 Carotid artery plaque composition – relationship to clinical presentation and ultrasound B-mode imaging. European Journal of Endovascular Surgery 10: 23–30
4. Bock RW et al Carotid plaque morphology and interpretation of the echolucent lesions. Diagnostic vascular ultrasound. Edward Arnold, London, pp 225–236 1992
5. Carotid artery stenosis: grey-scale and Doppler ultrasound diagnosis – Society of Radiologists in Ultrasound Consensus Conference' Grant EG et al Radiology 2003; 229: 340-346
6. Society for Vascular Technology Professional Standards Committee Image Storage Guideline April 2012